WHITECAP ACADEMY OF IMPLANT DENTISTRY MEMBER

WhiteCap Recap

JULY 2018

COME TO OUR ANNUAL SUMMIT

SEPTEMBER 20-21

Articles from Summit Speakers in this issue!

P.K. Clark, DDS

Riley Clark, DMD

Scott Froum, DDS

Paul Clark, DMD

In This Issue

UPCOMING COURSES - 2018

AUG	Adventure Series (2nd-4th, 9th-11th, 16th-18th, 23th-25th)
SEPT	Computer Guided Implant Surgery (7th-8th)
	Summit (20th-21st)
	ACLS Course (21st)
	IV Sedation Review (22nd)
OCT	3-Day Boot Camp (11th-13th)
	Advanced Bone Grafting (26th-27th)
NOV	Masters of Disaster (3rd)
	Computer Guided Implant Surgery (16th-17th)
DEC	3-Day Boot Camp (6th-8th)

Visit WhiteCapInstitute.com for registration and to view 2019 courses.

CLICK HERE TO PLAY VIDEO

Pearls To Ponder

For many years as a clinician you were faced with the decision of whether or not an implant is integrated and ready for restoration. Years ago we would tap the abutment with a mirror and based on the sound, make a decision. We may have looked at an x-ray to make a determination, or we based our decision on whether pus or blood were present. Later, we would use a torque wrench to see if it would spin out. Doesn't this all sound ridiculous as I talk about it? I am so excited that we now have technology to help in making this decision. It is as simple as placing a peg in the implant, and holding an instrument against the peg. This gives us a numerical number called an Implant Stability Quotient (ISQ). Historically these instruments have been amazing but they were overpriced and cumbersome. I recently tried an ISQ instrument out of Sweden called Penguin. It looks like an automated toothbrush and is priced at about $2,000.00. For three months I used and compared the Penguin ISQ reading to that of the very expensive Ostell ISQ. I was surprised and pleased that the read-out of both were the same. This technology has made it possible by scientific feedback to know that our implants are ready to restore. Also, by recording in a patient's chart their ISQ numbers at surgical phase, uncovery, and at the time of impressions, this becomes a great risk management tool. ***The Penguin is a game changer*** and a great pearl to ponder.

You have heard me say over and over again that "patient's don't care how much you know until they know how much you care". ***One of the ways I have found helpful in showing my care and appreciation is to call them by name two or three times during an appointment.*** For example, use their name in greeting and ask them how things are going for them, use it again as you begin to explain the treatment you will be doing. The second thing that helps to build strong relationships is to thank them for their confidence and business, and for being such a great patient in a difficult circumstance. All of these are a great opportunity to again call them by name. This leadership also sets a great example for your staff on the importance of making your patients feel comfortable and cared for. I promise you that if you use this pearl, it will pay great dividends for you and your practice.



By P.K. Clark

Dr. P.K. Clark is a practicing dentist, lecturer, and surgical mentor. He received his DMD from Oregon Health Science University and maintained a successful private practice in the Portland, Oregon area for nearly 20 years. After years of experience in his own growing practice and in teaching dentists one-on-one, Dr. Clark saw the immense change Implantology brings to general dentists and their patients. He saw a need to be filled and founded the unique WhiteCap Institute which has allowed him to spend time building relationships and teaching on subjects he is most passionate about. He is also able to continue expanding his skills and knowledge as he maintains an implant only practice in Utah. Both the clinical practice and the Institute are driven by the desire to offer exceptional patient-centered care.

Dr. Clark is also an active member of the dental community in societies including the International Congress of Oral Implantology, the American Academy of Implant Dentistry, the Academy of General Dentistry, and the American Dental Association.

Replacement Dental Implants

3 clinical methods to increase survival rates after initial implant failure

By Scott Froum, DDS

Scott Froum is a board certified periodontist who received his BA from Amherst College in Amherst, MA with a major in biology. He received his DDS from the State University of New York Stony Brook School of Dental Medicine where he graduated with honors. He continued his dental training in the post graduate periodontal department at the State University of New York Stony Brook School of Dental Medicine and received his periodontal certificate. He currently is a clinical assistant professor at the State University of New York- Stony Brook School of Dental Medicine in the Department of Periodontics. He is chief editor of the newsletter and web site Perio-Implant Advisory. He is on the editorial board for the Academy of Osseointegration Newsletter. He has published and lectured on the national and international level on periodontal treatment, implant therapy, and treating implant complications. He maintains a private practice in New York City, NY.

While dental implants traditionally are successful tooth-replacement options, complications can occur. Replacement with another implant is an option, but survival rates vary and have been reported to be in the range of 69% to 91%. Perio-Implant Advisory's Editorial Director Dr. Scott Froum discusses three clinical methods he uses to improve the survival rate of replacement dental implants following initial implant failure.

DENTAL IMPLANTS have traditionally enjoyed high survival rates as reported in the literature. (1) Complications can occur, however, and dental implant failure and removal have been reported to be in the average range of 5% to 12%. (2) After an implant is removed, the patient is left with a difficult decision regarding replacement options. (3) A removable prosthesis may be a possibility, but it is often not the first choice of therapy. A fixed partial denture on adjacent natural teeth can also be a treatment option if there is a single implant site failure. This option is predicated, however, upon the patient agreeing to preparation of the natural teeth as well as the abutment teeth having enough periodontal support to withstand the forces of a bridge. Most of the time, the patient will choose to replace the failed dental implant with placement of another implant.

Replacement of a failed dental implant with a second implant has varying survival rates in the literature, and have been reported to be in the range of 69% to 91%. (4,5) In addition to having lower success rates than the initial implants, replacement implants often require additional soft- and/or hard-tissue grafts, longer time to heal, new abutments/crowns, and possible additional financial costs for the patient. Prior to reimplantation, ascertaining the etiology of the initial implant failure is certainly warranted. In addition, methods to improve osseointegration of the replacement implant should be employed. *Following are three clinical tips this author uses to improve the dental implant survival rate after initial implant failure.*

1 Thorough removal of fibrous soft tissue from the dental implant socket

An implant that has lost integration can suffer from fibrous downgrowth (encapsulation) of the entire implant body (figure 1). This tissue acts a barrier to bone-to-implant contact and osseointegration of the replacement implant. (6) It is imperative to thoroughly debride the implant socket and meticulously remove all soft tissue prior to implant placement. Proper instrumentation will allow the clinician to reach the apex of the implant socket and be sharp enough to perform curettage on the osseous walls of the socket (figure 2). After complete tissue removal, chemical modification is the next step.

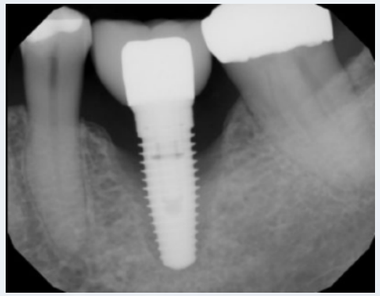

Figure 1: Radiograph showing complete loss of integration and fibrous encapsulation

Figure 2: Slade Blade socket curette (Paradise Dental Technologies) being used to remove fibrous soft tissue from the residual implant socket

2 Complete debridement of bacteria in the implant socket and surrounding tissue

Failing implants that are afflicted with peri-implantitis usually are exposed to the same pathogens that affect natural teeth. (7) These bacteria not only can coat an implant surface, but they also can be found in the surrounding peri-implant tissue. Complete removal of these bacteria via chemical detoxification of the residual implant socket and surrounding tissue can assist with removal of the pathogens (figure 3). Although both are effective, chemical modification with a neutral EDTA with a pH of 7.4 is a kinder alternative to tissue compared to 60% citric acid with a pH of 1. In addition, laser sterilization of the inflamed soft tissue surrounding the failed implant can help increase tissue tone during healing (figure 4).

Figure 3: Cotton pellets soaked with 60% citric acid used to detoxify an implant socket

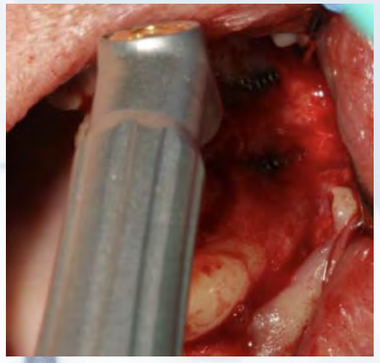

Figure 4: Laser sterilization of soft-tissue flap during implant removal to facilitate healing

3 Increase angiogenesis to the hard and soft tissue

Vascularity to the hard and soft tissue surrounding a dental implant is vital to its osseointegration. Because the implant surface itself is avascular, blood supply to the area is a challenge. When an implant fails, the vascularity of the surrounding tissue can be further damaged. Any enhancement to the angiogenic potential of the hard and soft tissue can only help a second attempt at implant placement. Decortication of the implant socket with a precision needle drill or round carbide has been suggested to increase blood supply to the area. The addition of exogenous growth factors and proteins—such as platelet-derived growth factor, leukocyte platelet-rich fibrin, enamel matrix derivative, and bone morphogenic proteins—have all been used to enhance the angiogenic response.

Although implant replacement after an initial failure has been shown to have a lower success rate compared with initial implant placement, the three methods discussed in this article can increase survival rates of reimplanted dental implants. Ultimately, an informed and honest discussion regarding the challenges of implant replacement should occur between the patient and the clinician before beginning any treatment. ■

References

1. Levin L, Sadet P, Grossmann Y. A retrospective evaluation of 1,387 single-tooth implants: a 6-year follow-up. J Periodontol. 2006;77(12):2080-2083. doi: 10.1902/jop.2006.060220.

2. Esposito M, Grusovin MG, Coulthard P, Thomsen P, Worthington HV. A 5-year follow-up comparative analysis of the efficacy of various osseointegrated dental implant systems: a systematic review of randomized controlled clinical trials. Int J Oral Maxillofac Implants. 2005;20(4):557-568.

3. Levin L. Dealing with implant failures. J Appl Oral Sci. 2008;16(3):171-175. doi: 10.1590/S1678-77572008000300002.

4. Duyck J, Naert I. Failure of oral implants: aetiology, symptoms and influencing factors. Clin Oral Investig. 1998;2(3):102-114.

5. Grossmann Y, Levin L. Success and survival of single dental implants placed in sites of previously failed implants. J Periodontol. 2007;78(9):1670-1674. doi: 10.1902/jop.2007.060516.

6. Zhou W, Wang F, Monje A, Elnayef B, Huang W, Wu Y. Feasibility of dental implant replacement in failed sites: a systematic review. Int J Oral Maxillofac Implants. 2016;31(3):535-545. doi: 10.11607/jomi.4312.

7. Quirynen M, Listgarten MA. Distribution of bacterial morphotypes around natural teeth and titanium implants ad modum Brånemark. Clin Oral Implant Res. 1990;1(1):8-12.

Team & Technology

A collaborative approach to implant placement

By Riley Clark, DMD

Riley, Clark, DMD, completed his Bachelor's degree in biological sciences at Portland State University and then moved to Cleveland, Ohio, for his DMD program at Case Western Reserve University. Shortly after graduation he attended advanced training in anesthesia. Professionally, Dr. Clark takes great pride in optimizing clinical efficiencies and digital workflows. He spends the majority of his time in private practice doing full-mouth dental implant rehab. Dr. Clark also teaches and mentors at WhiteCap Institute. He acts as a consultant to WhiteCap Dental Lab and Milling, where he focuses on full-mouth treatment sequencing and digital workflows in preoperative procedures and fainl restorative procedures. Dr. Clark is passionate about dentistry and transforming patients' lives through their smiles with dental implants.

Disclosure: Dr. Clark is a key opinion leader for Carestream Dental.

Our teaching institute emphasizes practical education. A hallmark example of this is our "one-on-one" mentoring program. This collaborative approach is powerful, as doctor colleagues work together with one goal in mind - achieve the best treatment outcome for our patients. Embracing digital planning in our mentoring program has proven a powerful aid to our doctors' ability to deliver better care for their patients. Digital technology opens doors to procedures that were never thought possible. In this case, an out-of-state doctor did more than just refer her patient to our institute for treatment, but traveled with him to gain hands-on experience with our technology and perform the surgery alongside my father and me. She walked away from the case impressed with how virtual surgical panning (VSP) and cone beam computed tomography (CBCT) augment surgical and prosthetic outcomes. Most importantly, the patient walked away with an amazing result.

The male patient, presented at the referring doctor's office, was in need of a full-mouth rehab. Treatment options included crown-and-bridge work to salvage the remaining teeth with conventional restorative methodology, extraction, and dentures, or a fixed implant solution. The patient opted for impants. Our mentoring program often lowers the barrier to entry that all our patients struggle with - price. For a fraction of the "retail" price, our mentoring doctors are able to offer premium implant services at a more manageable fee. To start designing the case, a PVS impression, bite registration, and a CBCT scan were taken by the referring doctor.

The traditional impression was digitiazed by our lab, WhiteCap Dental Lab and Milling, and the STL file and DICOM from the CBCT were then merged in Dental Planning Software (DPS) (360imaging®))(Figures 3, 4). Multiple implants were planned (Figure 1) with two thoughts in mind - first, maximize the primary stability of each implant, and second, ensure the implants were in an ideal restorative position (Figure 2). To achieve this outcome, a digital wax-up was used (from exocad) in the planning phase. The digital wax-up was also used to finalize both full-arch temporaries - in this case, milled polymethylmethacrylate (PMMA) (Figures 5, 10).

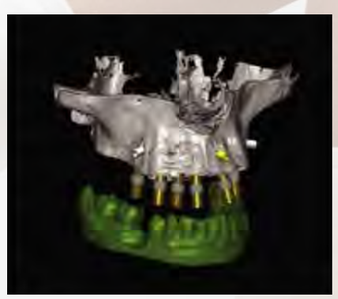

Figure 1

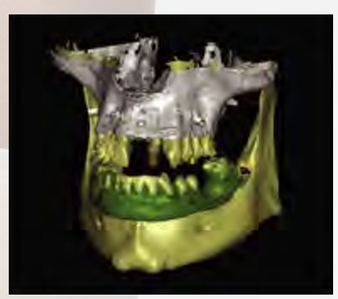

Figure 2

With both implants and temporaries planned, next we chose what guide type/design would act as the vehicle to deliver this product to the patient. A variety of options are available for such a case. Because of our partnership with 360imaging, we were thrilled to use a new type of guide that, at the time, had a patent pending. This ingenious design features a buccal bone support, called the anatomical guide, to which all components of the case would seat to utilizing their patented diamond latch system. This leads to incredibly accurate relationships of the planned implants relative to bone and to the premade lab temporaries. Another highlight is the anatomical guide is seated from a vertical stop referenced to the natural teeth (Figures 6, 11). This case along with its thoughtful guide design, epitomizes clinical accuracy and efficiency in full-mouth implant rehab (Figures 7-9).

To summarize some benefits of the diamond latch guide:

- Up to 75% smaller than comparable guides
- Requires no lingual or distal tissure reflection
- One point of reference for all attachments (including vertical seating piece, implant guide, PMMA)
- Increased accuracy compared to other guide systems
- Stronger compared to other guide systems

On the day of surgery, the patient was moderately sedated via IV access and locally anesthetized with Septocaine®. We started on the maxillary arch. The guide protocol dictated that a few teeth be removed first to ensure a passive fit of the anatomical guide and the vertical

cont. pg 10

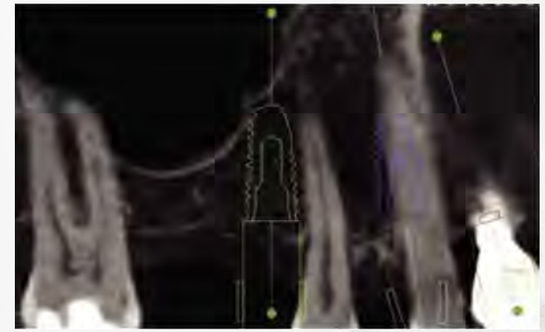

Figure 3

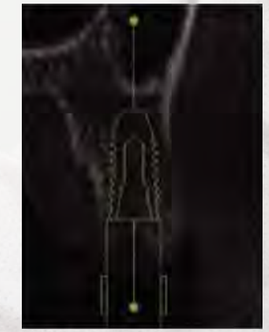

Figure 4

Figure 5

Figure 6

Figure 7

Figure 8

Figure 9

Figure 10

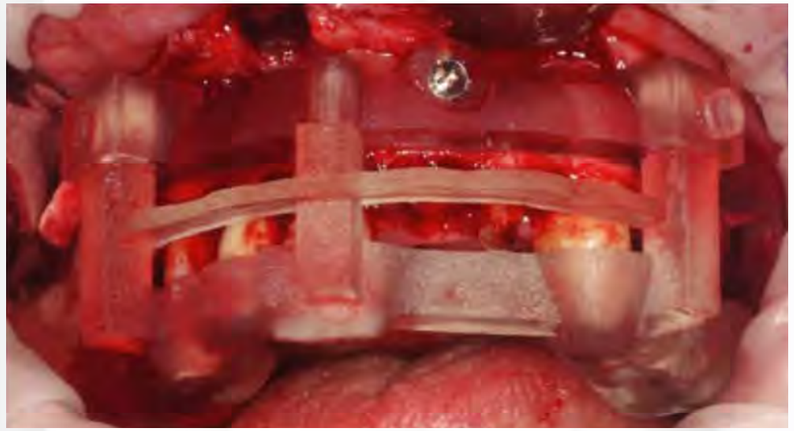

Figure 11

stop over the remaining maxillary teeth. After those few teeth were removed, a buccal flap was reflected, and the anatomical guide was seated to the buccal plate with the help of the vertical stop resting on the occlusal surface of the maxillary teeth (Figure 11).

After the anatomical guide was fixated to the buccal plate and the vertical stop removed (Figure 12), all remaining teeth were extracted (Figure 13), leaving No. 2. Tooth No. 2 and No. 31 were deemed helpful with this case by acting as a occlusal stop and providing proprioceptive feedback to the patient during the healing phase of the implants. One novel benefit of this guide design is the addional support the buccal plate has. Often during extractions, a thin (and sometimes not so thin) buccal plate can be fractured and may mandate a change in implant position. The anatomical guide supported the buccal plate and protected the bone from excessive trauma during the extractions. After extractions, bone reduction was done using the anatomical guide as a reference. With the teeth removed and the bone reduced, it was time to thoroughly debridge the extraction sites with a curette and rotary side-cutting bur.

Next, the implant guide was secured to the anatomical guide with two horizontal pins in the posterior and one vertical stop at the anterior (this is referred to as the diamond latch system). The implants were placed following the drilling protocol to maximize primary stability (Figure 14). Then the implant guide was removed from the anatomical guide, and non-hexed, temporary metal cylinders were placed in all implants. The cylinders were visually determined based on their relative position on the lab printed analog model (Figure 15). Seating jigs were not used for this process because minor changes in the implant position often exist and deem the seating jigs useless. After the cylinders were placed, bone grafting was performed in extraction sites around implants. Then dermal tissue was taken, with holes punched so it could fit over the temporary cylinders to cover the alveolar ridge. The use of dermal tissure leads to a thicker connective tissue layer after healing.

At this point, the surgical phase of the treatment was put on hold, and the temporary PMMA was seated (Figure 16). Again, the genius of this guide system is designing the diamond latch system into the PMMA (Figure 9). In this design, the anatomical guide served as a constant landmark to which all other components were referenced. Minor adjustments were made to ensure ideal spacing for "pick up" material around the temporary abutments. A tissure spacer was placed between the PMMA and the dermal tissure. The "pick up" was done with a dual-cure resin with the PMMA securely attached to the nantomical guide. The PMMA diamond latches were cut off, allowing the anatomical guide to be unscrewed from the buccal plate. The PMMA remained fixed to the implants, however; and suturing was done around PMMA. This PMMA "pick up" process took about 30 minutes (Figure 17).

The same procedure was repeated on the lower arch. Our "pick up" procedure followed a more traditional approach of removing the PMMA and making adjustments extraorally, while suturing procedures were completed. Ultimately, the lower "pick up" approach was advantageous because of the time efficiency and ability to contour the intaglio of the PMMA more exactly. Occlusal adjusted and refinements were made to the fit and feel of the PMMAs (Figure 18).

Postoperative CBCT scans were taken with a CS 8100 3D (Carestream Dental) to provide a baseline and track healing (Figures 19, 20). The patient will begin final restorative procedures in 5-7 months.

Figure 12

Figure 13

Figure 14

Figure 15

Figure 16

Figure 17

Figure 18

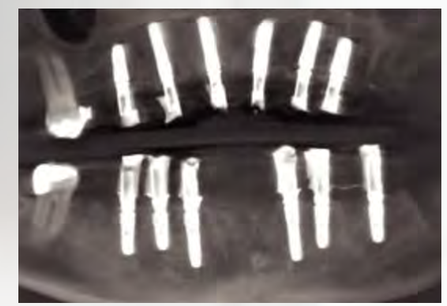

Figure 19

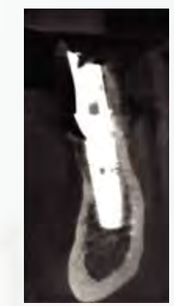

Figure 20

What made this case predictable and even possible? The answer is the synergy of a thoughtful clinical team and powerful technology. Technology helps us execute surgical and prosthetic rehabilitation with accuracy and efficacy. Technology allows us to convert complex cases into manageable and practical cases. In fact, I would say the least stressful part of the entire case was placing the actual implants, which was historically the most stressful part of these cases when I was freehanding implant placement. From the technology, to the labs and their technicians, to the mentoring doctor, to the assisitants, to the patient, this was a collaborative effort, and I would call the case a collaborative win. ■

Acknowledgments
- Dr. Evon Heaser, Mentoring Doctor
- 360imaging®, Mark Palmer, CEO
- Dr. P.K. Clark, WhiteCap Institute, Clincial Director
- WhiteCap Dental Lab and Milling, Jim Campbell, Guide Department Manager
- WhiteCap Dental Lab and Milling, David Nowaskey, CAD Department Manager

Figure 21 - 2 weeks post-op

Planning an anterior esthetic implant case with innovative technologies

Improved workflow due to digital technologies & a skilled lab

By Riley Clark, DMD



Riley, Clark, DMD, completed his Bachelor's degree in biological sciences at Portland State University and then moved to Cleveland, Ohio, for his DMD program at Case Western Reserve University. Shortly after graduation he attended advanced training in anesthesia. Professionally, Dr. Clark takes great pride in optimizing clinical efficiencies and digital workflows. He spends the majority of his time in private practice doing full-mouth dental implant rehab. Dr. Clark also teaches and mentors at WhiteCap Institute. He acts as a consultant to WhiteCap Dental Lab and Milling, where he focuses on full-mouth treatment sequencing and digital workflows in preoperative procedures and fainl restorative procedures. Dr. Clark is passionate about dentistry and transforming patients' lives through their smiles with dental implants.

Disclosure: Dr. Clark is a key opinion leader for Carestream Dental.

When patients opt for implant-supported prosthetic rehabilitation, their questions focus most frequently on prosthetic implications, not the implant surgery. Questions arise, such as: "Am I going to leave surgery with teeth? What will the teeth look like? How will the teeth function?" Fortunately, a digital workflow allows implantologists to give patients not only predictable surgical outcomes but also a familiar temporary on the day of surgery.

With today's technology and with a good lab, the implant dentist can not only plan the ideal implant position relative to osseous boundaries but also complement those implants with milled abutments and provisionals. Perhaps the most compelling aspect is that these processes can occur days before the surgery even happens. Nothing highlights this technology and its potential better than an anterior esthetic case as will be demonstrated in this review.

A 44-year-old male presented with complaints of pain and pressure around an existing bridge from teeth Nos. 6-10. The patient received recommendations from colleagues to seek out treatment at WhiteCap Institute due to its capabilities in using technology to plan for immediate placement of dental implants and provisional crowns. After a clinical exam, decay was found on tooth No. 6, which was supporting the bridge. The tooth would need to be extracted. The patient worked in a highly visible position and was hesitant to settle for teeth that weren't perfect and did not like the idea of a long span bridge involving more abutment teeth. He opted for an implant-supported bridge using three implants.

A CBCT scan was captured with a CS 8100 3D system (Carestream Dental) (Figure 1), and a digital impression was taken with a CS 3600 intraoral scanner (Carestream Dental) (Figure 2).

The patient's CBCT (DICOM) file was merged with the STL file produced by the CS 3600 using Carestream Dental's Prosthetic-Driven Implant Planning module (Figures 3, 4). The implant position was then digitally planned (Figures 5, 6).

These files were exported to WhiteCap Dental Lab and Milling, which utilizes 360imaging® software to plan and fabricate surgical guides (Figure 7). Implant locations are shown through the simulated surgical planning software (Figures 8, 9).

Figure 1: CS 8100 3D 8x9 FOV at 150µ

Figure 2: Digital impression taken with a CS 3600 intraoral scanner

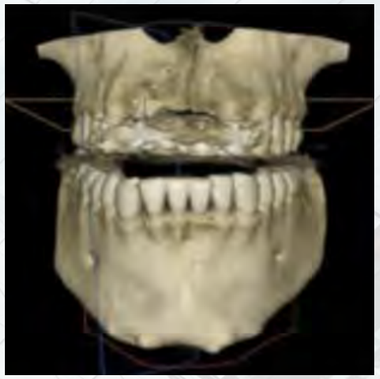

Figure 3

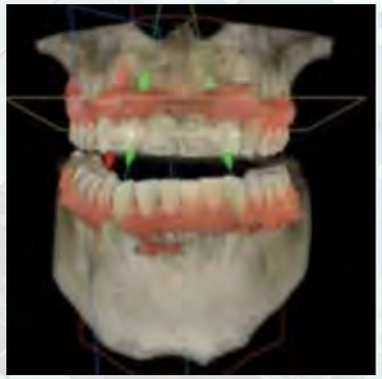

Figure 4

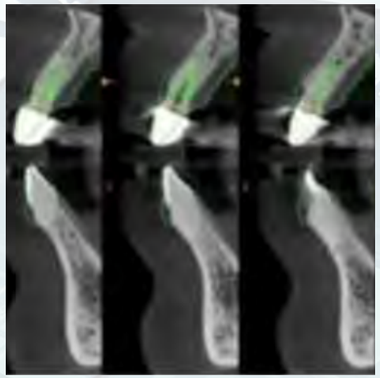

Figure 5

Figure 6

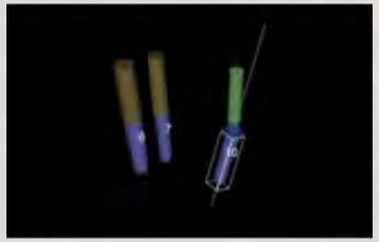

Figure 8

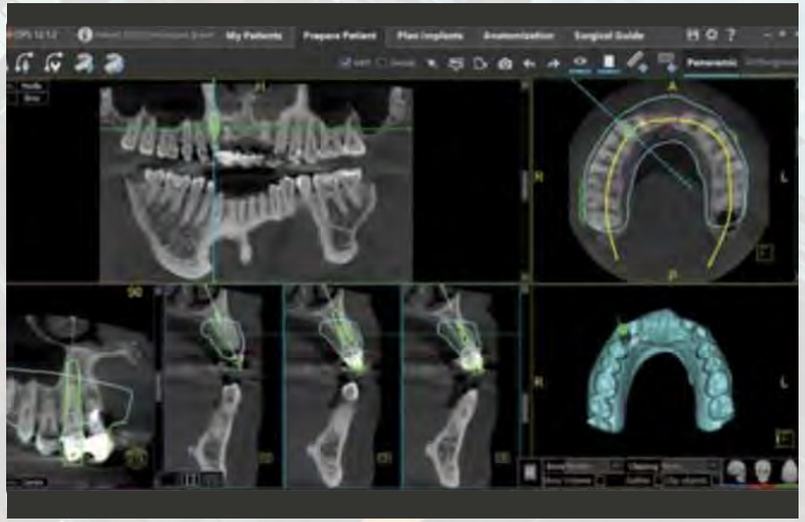

Figure 7

This data was merged with prosthetic planning software (exocad) (Figure 10) from which an immediate fixed provisional bridge was designed (Figures 11, 12). The interface of these technologies allows not only precise implant placement planning, but also the fabrication of capable and esthetic temporaries.

cont. pg 14

TREATMENT

On the day of the surgery, blood was drawn and processed following the Endoret® (prgf®) protocol (BTI®). An IV line was placed, and the patient sedated to a light/-moderate level; 4% Septocaine® 1:100k epi was administered to the anterior maxilla for local anesthesia.

The first task was to section the bridge between teeth Nos. 6 and 7 and then between Nos. 7 and 10. Abutment teeth Nos. 6, 7 and 10 were extracted following an atraumatic protocol in order to preserve the buccal plate and other periodontal tissues. The lateral incisors were extracted quickly and uneventfully. However, tooth No. 6 needed to be sectioned to remove it with minimal pressure and trauma to its supporting structures (Figure 13). The sectioning of single-rooted teeth is helpful for atraumatic exodontia when traditional methods prove fruitless. A small periapical cyst was discovered on tooth No. 7. A fair amount of time was spent between irrigation and manual/rotary debridement to remove any cystic remnants. Often a rotary instrument, such as a Lindermann bur, at the apical end of the extraction is the best approach for apical depridement.
At that point, the surgical guide was placed, and proper fit was confirmed (Figure 14). A fixation pin in the anterior portion was placed to add extra stability to the guide during drilling.

The designated drilling sequence was followed with a special focus to not oversize the osteotomy. Immediate placement of implants requires distinct attention during drilling to achieve primary stability. Without initial stability, the implants would have needed to follow a two-stage protocol, and

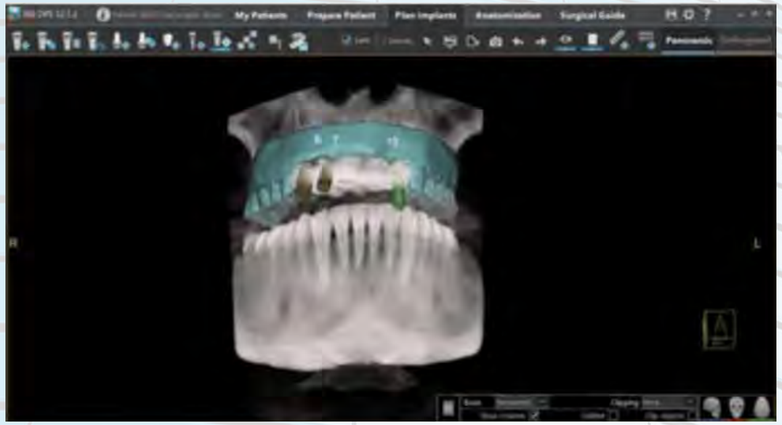
Figure 9

no fixed temporary could have been indicated the day of surgery.

After the osteotomy drilling, the surgical guide was removed, and a 50/50 mixture of bovine bone and cadaver bone that had been embedded in the PRGF mixture was placed into the extraction areas, mainly against the buccal plate. Then the surgical guide was seated, and the three implants were placed through the surgical guide using a special mount to ensure proper position within the guide (Figure 15). Initial stability was achieved on every implant. The surgical guide was removed, and supplemental bone grafting was performed where needed.

Tooth No. 10 had a special task to ensure that the rotational component of the implant was ideal for a 17˚ multi-angled abutment. The abutment was tried in; the angle was slightly off, so the implant was rotated 10˚ to 15˚; and the abutment was tried in again (Figure 16.) The new angle fit the profile we were hoping to achieve. Lab-prepped temporary cylinders were placed direct to implants on teeth Nos. 6 and 7. No. 10 cylinder was placed on the multi-unit abutment following the corrected 17˚ angle, maximizing parrallelism between all abutments (Figure 17).

At that point, it was confirmed that the PMMA temporary could fit passively over all three abutments (Figure 18). After confirming a good fit and occlusion, PRGF fibrin membranes were placed around the temporary abutments.

A luting agent was used to adhere the PMMA bridge to the abutments. Small holes and voides were filled in. The occlusion was checked and the bite adjusted to avoid anterior collision with the temporary (Figures 19-21).

The out-of-town patient returned the following day for a post-op visit to check bite and initial patient response (Figure 22).

After 3 months of healing, the patient will return to have another digital impression taken with the CS 3600 for the restorative phase. ■

Figure 10


Figure 11


Figure 12


Figure 13


Figure 14


Figure 15


Figure 16


Figure 17


Figure 18


Figure 19


Figure 20


Figure 21

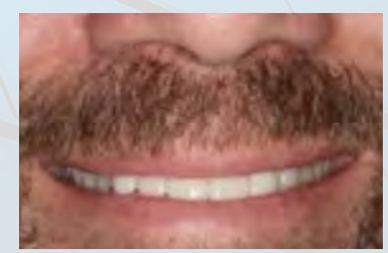
Figure 22

Today's Zirconia Options:
Esthetics vs. Strength

Today, Zirconia is considered a viable restorative material within the Dental Industry. Over the years, technology has obviously improved its accuracy, strength, and esthetics. Still, it is important to recognize its limitations and place in Restorative Dentistry. One formulation of Zirconia does not meet the criteria for all restorations, particularly with implants. Today there are several types of Zirconia available to meet the various needs presented to you from your patient.

Jeffery Dee Anderson, CDT
WhiteCap Lab & Milling Manager

Jeff began his career in 1976 by attending the Dental Technology Program at San Francisco City College. Upon his graduation, he was recognized by the Northern California Dental Lab Association as "Outstanding Student" of his class. Jeff has over 40 years of experience in assisting doctors and their practices, by providing simple solutions and assistance with the latest technologies and materials. Jeff was among the first group of dental technicians in Utah to be trained to specialize in dental implants. Jeff is pleased to be a part of Whitecap Institute, and to share his skills and knowledge with you. Jeff is the Father of 3 children and 2 grandchildren, and currently resides in Heber City, Utah with his wife, Leslie.

With Zirconia, one should recognize that esthetics come at the cost of strength, while strength comes at the cost of esthetics. Esthetic Multi-Layered Zirconia can provide a beautiful monolithic restoration, but it is limited by strength requirements to singles and some 3-unit bridges, and usually only on natural teeth.

Unfortunately, most implant restorations require the stronger, more opaque Zirconia to meet their design requirements.You should also note that all Zirconia is shaded only in Vita Classic Shades, thus any other shade you request is customized in the laboratory. For this reason, there are challenges and limitations to get exact shading on the stronger Zirconias, and why layering with e.max porcelain is often still necessary. The reality may be disappointing, but the laboratory does its best to meet the individual needs of each case within the criteria you and your patient request. ■



WhiteCap
DENTAL LAB & MILLING